

Received: 2012.12.12
Accepted: 2013.03.08
Published: 2013.05.27

Muscle activity in the course of rehabilitation of masticatory motor system functional disorders

Ćwiczenia mięśni w rehabilitacji zaburzeń czynnościowych układu ruchowego narządu żucia

Authors' Contribution:

- A** Study Design
- B** Data Collection
- C** Statistical Analysis
- D** Data Interpretation
- E** Manuscript Preparation
- F** Literature Search
- G** Funds Collection

Edward Kijak^{1, A, B, C, D}, Danuta Lietz-Kijak^{2, B, E, F}, Zbigniew Śliwiński^{3, D, G},
Bogumiła Frączak^{1, A, F}

¹ Department of Prosthodontics, PUM in Szczecin

² Department of Propedeutics and Oral Physicodiagnostics, PUM in Szczecin

³ Institute of Physiotherapy, Jan Kochanowski University in Kielce

Summary

On the basis of selected cases, evaluation of the usefulness of muscular exercises in rehabilitation of patients stricken by a dysfunction of the motor system of the chewing organ was accomplished. The assessment of the electric function of chewing muscles together with the registration of mandibular movements with the axiographic Zebris JMA apparatus was made, both before and after muscular therapy. The examination has shown that regardless of micro- or macro-traumatic cause, the set of muscular exercises appropriately selected and dutifully carried out is able to restore full condition of the motor system of the bone-dental structure effectively.

Keywords: dysfunction of the temporomandibular joints (TMJ) • muscle activity

Full-text PDF: <http://www.phmd.pl/fulltxt.php?ICID=1051002>

Word count: 3115
Tables: –
Figures: 11
References: 21

Author's address: Edward Kijak, Ph. Department of Prosthodontics, PUM in Szczecin, Poland;
e-mail: zd.protetyki.stom@pum.edu.pl

INTRODUCTION

The proper functioning of the stomatognathic system is achieved by dental and musculo-nervous system harmonious interaction. If either of these two systems fails, it leads to the stomatognathic system's motor apparatus impairment.

The syndrome of masticatory dysfunctions is a group of civilization diseases with increasing frequency. Epidemiological studies in recent years, regarding the ele-

ments causing functional changes in the stomatognathic system, show that the most important are malocclusion (54%), stress factors (34%), mental disorders (7.1%) and the primal, partly generalized disorder arthritis (4.1%) [11,14,18,22,28].

Dysfunction is often accompanied by various types of parafunctions (e.g. bruxism)[21]. Among the determinants that cause dysfunction in the stomatognathic system most often the following are mentioned: traumatic occlusion, stress, wrong habits, acute and chronic inju-

ries, muscles' dysfunctional features and iatrogenic issues [9,22,31]. Dysfunction of the masticatory motor system persisting for years causes over time occurrence of pain symptoms or painless signs, referred to as dysfunction. The main symptoms of masticatory dysfunction are: pain during mandibular movements, limiting its mobility, and leaping and crackling in the TMJ. It is assumed that at least one of these symptoms occurs in about 90% of the human population.

One of the early masticatory dysfunction signs is mandibular mobility model disorder. The study of uninterrupted articulatory jaw movement is the basis of clinical evaluation of masticatory efficiency.

As a rule, diagnostics of stomatognathic system dysfunction is carried out on data from medical inquiry and clinical examination: visual, auscultatory and palpable. Due to the increasing prevalence, diversity and growth in the disease process intensity, simple clinical tests seem to be insufficient. The use of modern, often elaborate diagnostic techniques becomes indispensable, especially for patients with severe symptoms of stomatognathic system dysfunction, frequently combined with morphological changes [2,3,12,15,22,24].

Medical tests including the muscular system are integral to masticatory efficiency assessment. Clinical evaluation includes the size of each muscle, its symmetry, determining the level of tension, activity and pain sensitivity. The survey is performed by palpation, but also as static and dynamic function tests. More reliable muscle function exploration is electromyographic study [4,8]. That allows one to determine numerical values of resting and functional potentials and makes it possible to assess homologous muscles in terms of symmetry [4,13,30]. The muscular system, responsible for the movements of the jaw, is a geminate system. As a result of some muscles' contraction and relaxation of antagonistic muscles, the mandible after receiving impulses from the nervous system is set in a particular position. Therefore, symmetrical muscular work is one of the most important initiators conditioning the proper functioning of the masticatory system.

Muscles important for the treatment of masticatory movement disorders are mandibular adductors: masseter, temporal muscles, internal pterygoid muscle and mandible abductor – external pterygoid muscle, and to a lesser extent, the bottom of the oral cavity muscle, as well as the tongue, throat and palate muscles. The whole layout's agile functioning, due to the overriding role of the CNS, depends not only on the patient's psycho-emotional condition, but also on overall health. Physiological and pathological processes, taking place even in tissue located far from the masticatory system, through neural connections, can reach the masticatory system and affect its function. In the literature there have been reported cases of pain transferred to the stomatognathic system from the chest and even from the

abdominal cavity [9]. The management among patients with motor dysfunction of the masticatory organ is an extended, intricate and generally multistage process. Possible therapeutic procedures are very diverse. In diseases associated with particular disc displacement, at the forefront lies therapy using the great variety of bite splints. The aim is, inter alia, articular disc repositioning, reducing excessive stomatognathic system muscle tension and the restoration of static and dynamic symmetry in all parts of the system [25].

In episodes with notable severity of disease symptoms caused by dysfunction, pain or acoustic effects, which affect the patient's psyche, there is often a conscious restriction of chewing muscle function. Muscular therapy in such cases is sufficient to achieve a satisfactory therapeutic effect. Lack of muscle activity is just as harmful to the stomatognathic system components as their hyperactivity in e.g. bruxism. This may lead to shortening of muscle fibres, in extreme cases even to muscle atrophy. Muscles' training, recommended for patients suffering from stomatognathic system macro-injuries, is often the only chance to restore the efficiency of the damaged items.

DESCRIPTION OF THE CASES

Case I

Patient Z.N., aged 20, case history 12/N/2007, reported herself to the Department of Dental Prosthetics, Pomeranian Medical University, for diagnosis and conservative treatment. The treated woman complained that for approximately four months she had suffered from crackling and skipping movements in the left temporo-mandibular joint. Dysfunctional symptoms, in addition to the patient's discomfort and anxiety, did not cause any pain. Clinical palpable trial indicated no masticatory muscles' tactile soreness. Masseter and temporal muscles showed no sign of increased tension. Both dental arches were complete with a few fillings, secured type of articulation by canines and incisors, no signs of pathological encounter or occlusal obstacles. The patient was not being treated orthodontically.

On the day of the study major symptoms reported were: abduction of the mandible limited and with difficulties (26 mm measured with a ruler), with marked right-sided deviation of the mandible in the first movement phase. On the basis of X-rays, according to Schüller a bilateral movement reduction of the mandibular head was concluded.

In the functional procedure conducted by Zebris apparatus, there was an abridgement of abduction movement (27.7 mm) and lateral movements – about 6 mm (Fig. 1 B).

In the electromyographic study performed using the Zebris Dental Bluetooth System for recording and analyzing EMG, there was no increased muscle tension or potential differences between right and left sides (Fig. 3).

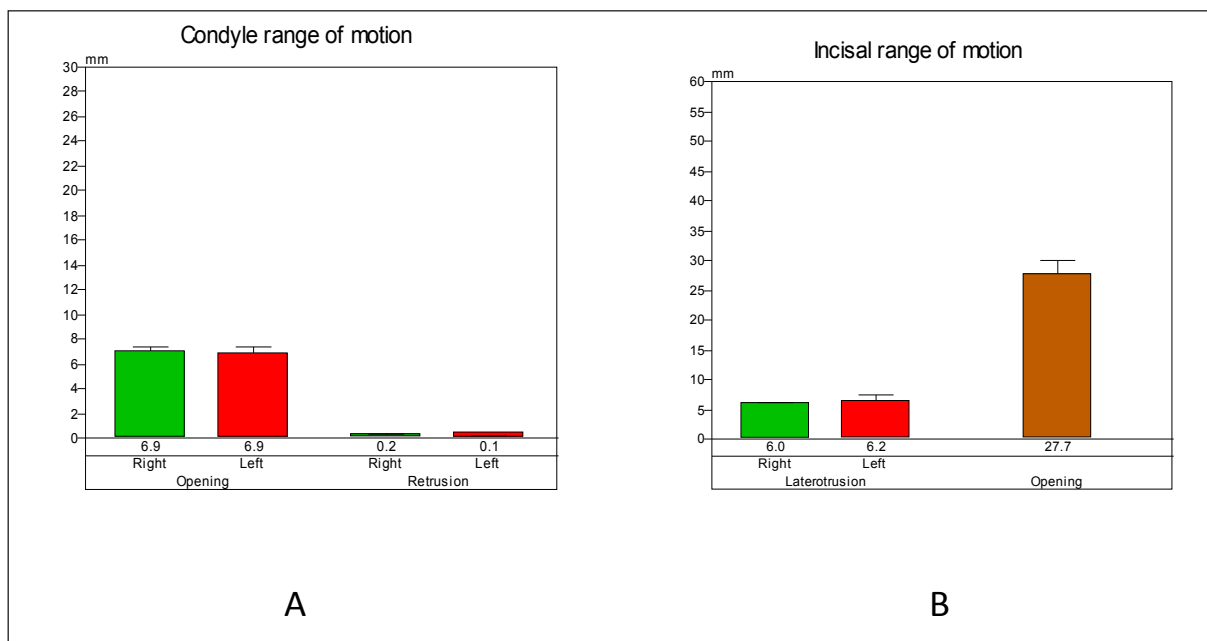


Fig. 1. Recordings of general abduction report using Zebris JMA device

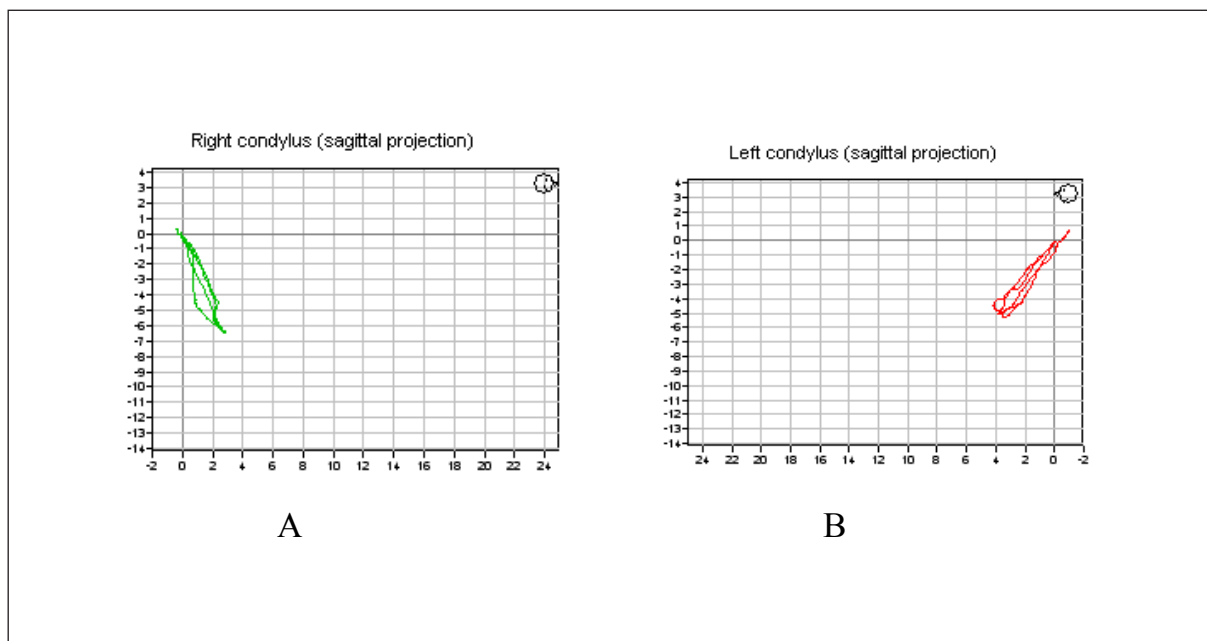


Fig. 2. Graphic notation of condylar movement using the Zebris JMA device. A - the right joint; B - the left joint

Moreover, action potentials showed no significant differences either in terms of value or in the homologous muscles' symmetry.

Based on the above-mentioned symptoms and test results, the diagnosis was the disturbance model of abduction of the mandible and reduction of mental source. A set of exercises was presented to the patient: training that corrects the jaw's movable model – opening along the straight line, in front of the mirror and stretching exercises

to increase mobility of the mandible – gentle strength application coming from the patient's fingers. As prescribed, the instructions had to be performed 2-3 times a day in batches of 15 to 20 repetitions. After six weeks of therapy, a significant improvement was observed. The results of the performed functional research, obtained with the Zebris JMA device, show a marked increase of motion range. The size of the opened mouth was 36.3 mm, which is an increase of nearly 9 mm (Fig. 4A), and lateral motions: right sided – 8.8 mm, left-sided – 7.6 mm.

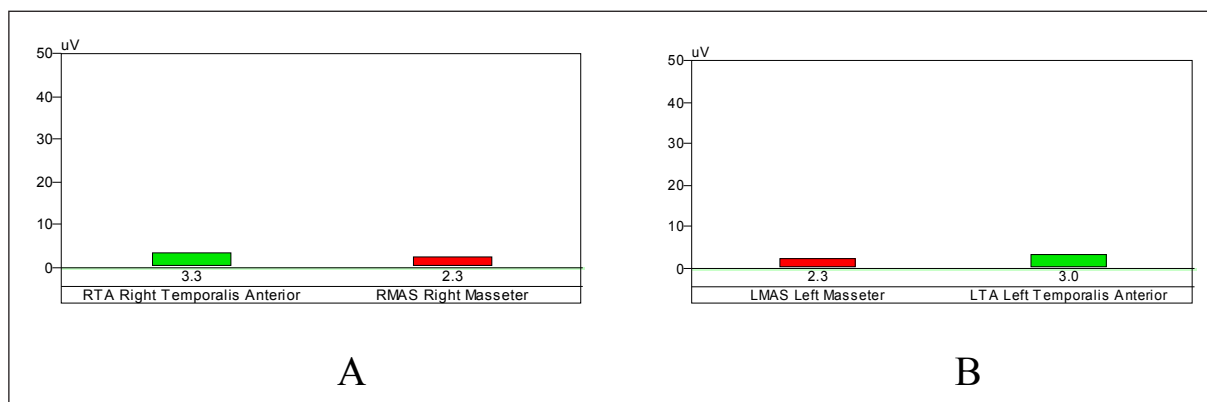


Fig. 3. Section of patient's electromyography broad report (Zebri EMG) - resting potentials' values. A - right side, B - left side. Red colour - masseters, green colour - temporal muscles

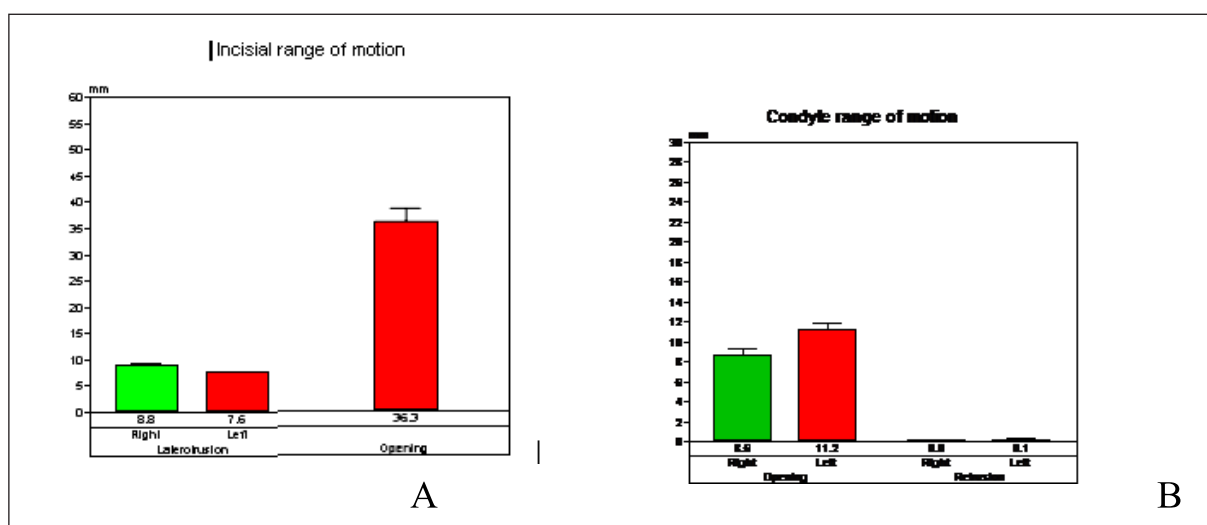


Fig. 4. Graphic recording (Zebri JMA) of patient's condylar movement after 6 weeks of muscle training: A – opening and lateral movement range, B – motion range of both condylar appendices in the joints

Case II

Anamnesis: Patient T.M., aged 25, referred to the Department of Dental Prosthetics, Pomeranian Medical University, with pain from the temporomandibular joints. A sore appeared about 2 months previously, in the area of the temporomandibular joints and the two angles of the mandible with indication to the left side. With wide open mouth (yawning) there was noticeable leaping in both TMJs. At the time of examination, after taking non-steroid anti-inflammatory drugs the pain disappeared. The patient noticed that after discontinuation of drug treatment the aches recurred. Pain symptoms occurred before, but never with such high intensity, which continued for 2 months. The patient associated the fact of worsening symptoms with wide mouth opening while yawning. The biggest annoyance of symptoms occurred in the morning shortly after getting up. During the day the pain intensity diminished, but intensified during chewing.

Clinical examination revealed excessive mobility of the mandible (the interval measured between the cutting edges of upper and lower incisors was 47 mm), the occurrence of significantly impaired mandible's track with left-sided direction of deviation during abduction, and increased masticatory muscle tension, especially in the masseter and temporal muscles. The intra-oral study revealed upper dental arches with standard overlapping and without dysregulation in teeth positioning. On radiographs showing the temporomandibular functional joints according to Schüller subluxation of the left condylar appendix was identified (Fig. 5).

The functional study, using the Zebri JMA axiograph device, exhibited increased motion range of both condylars – 20.6 and 20.2 mm right-left (Fig. 6A), increased size of opened mouth – 48.8 mm, and bilateral restraint of lateral movement: 4.1 mm right-sided and 4.9 mm left-sided (Fig. 6B).

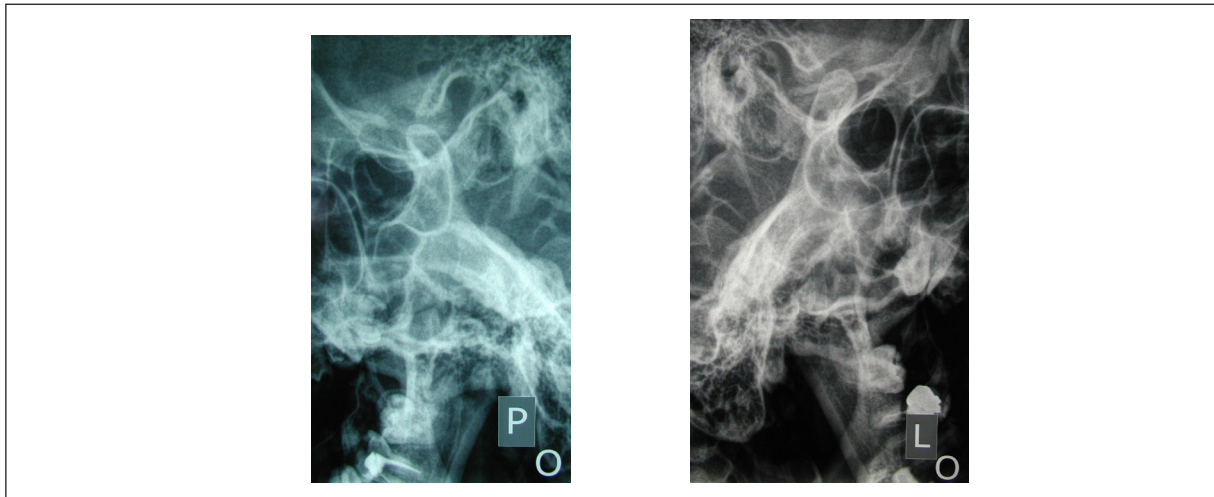


Fig. 5. X-ray images of the temporomandibular joints. Patient's mouth is open (according to Schüller)

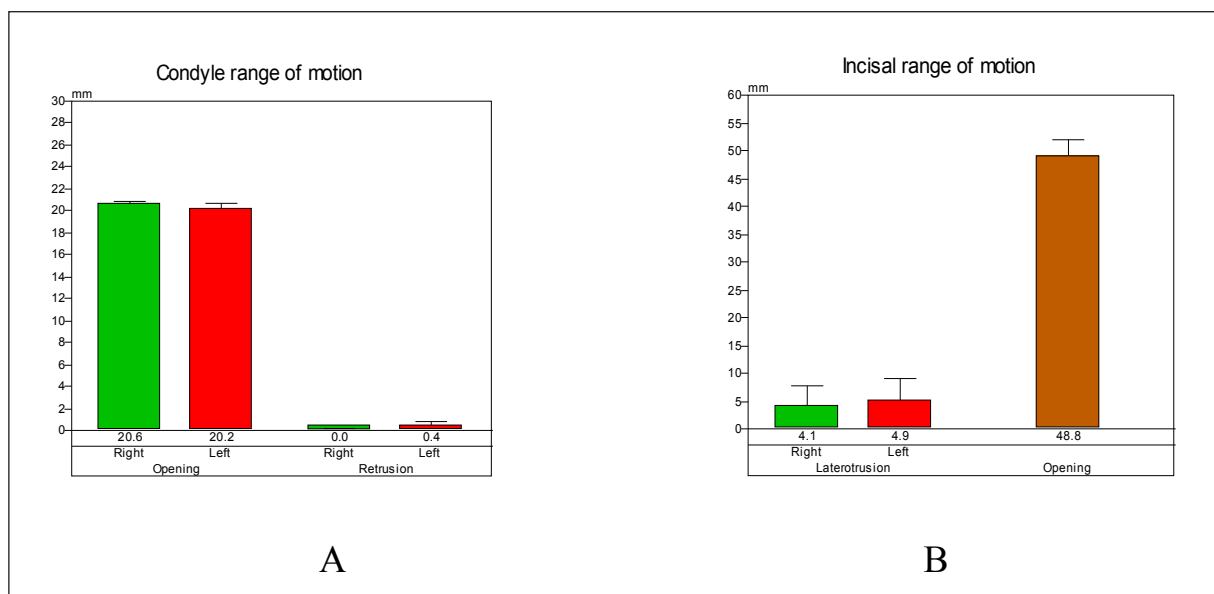


Fig. 6. Graphic recording (Zebbris JMA) of patient's condylar movement: A – motion range of condylar appendixes in the joints. B - opening and lateral movement range

Symmetric range of condylar appendixes' motion connected with axiographs (Fig. 7) indicated more the excessive mobility of both jaw heads rather than for one-sided subluxation.

The patient was instructed how to accomplish a set of exercises: limiting the size of the aperture – opening the mouth with handling the tip of the tongue to the palate surface and training correcting the jaw's movable model – opening along the straight line, in front of the mirror. As prescribed, the activity had to be performed 2-3 times a day in batches of 15 to 20 repetitions.

Required physical therapy resulted in marked improvement of the masticatory system's functional position

and the patient's well-being. Follow-up tests performed after 2 months, using the Zebbris JMA apparatus, registered significant reduction in the range of opening motion and a slight increase in the range of laterotrusion: right-sided to 6 mm, left-sided to 5.8 mm (Fig. 8A). The size of mouth orifice opening was by 41.8 mm longer, which is about 7 mm less. There was also a shorter length of the articular way of both condylar processes, which due to exercises was reduced by about 3 mm (Fig. 8B).

Case III

Patient R.B., aged 19, presented to the Department of Dental Prosthetics, Pomeranian Medical University,

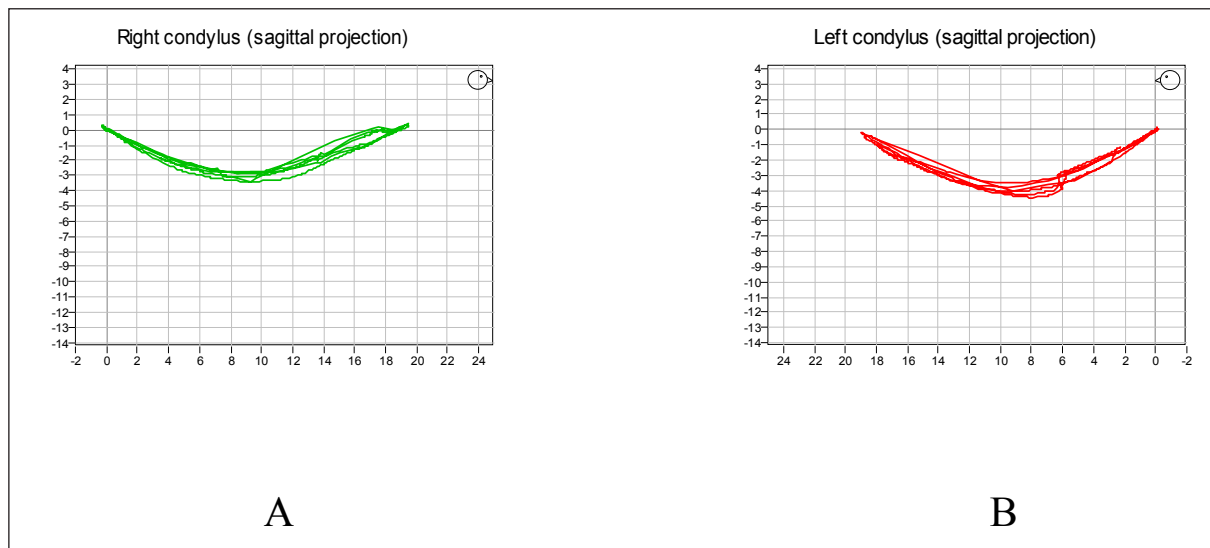


Fig. 7. Graphic recording of condylar appendices motion connected with axiographs indicated more the excessive mobility of both jaw heads' movement using the Zebris JMA device

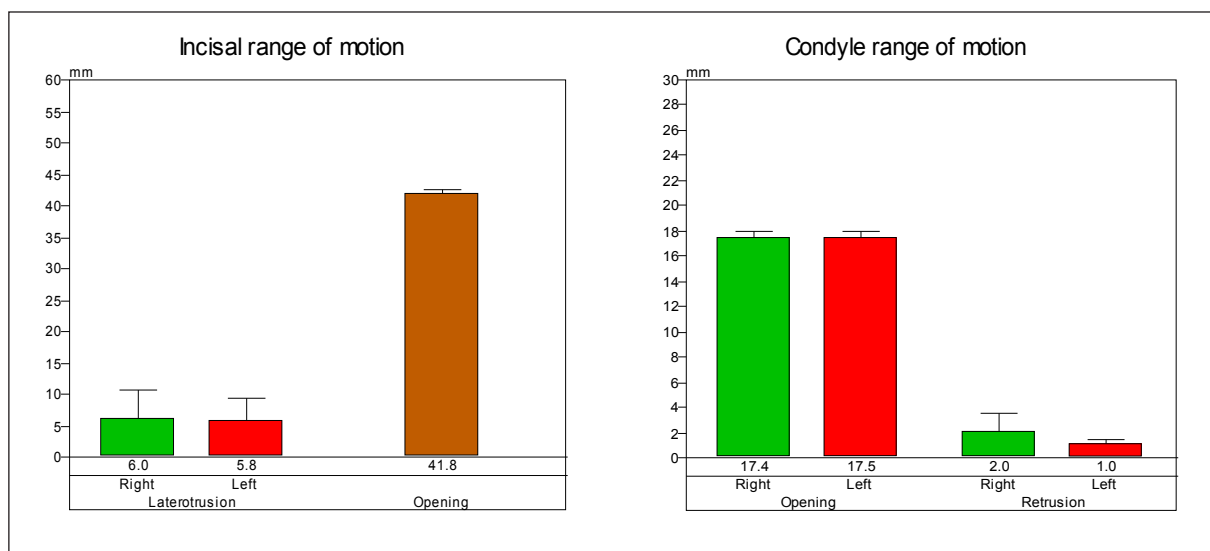


Fig. 8. Graphic recording (Zebris JMA) of the patient's condyle of mandibular movement and incisal point, after 8 weeks of training: A - opening and lateral movements' range; B - motion range of both condylar heads in the joints

for treatment. The patient received a referral from the Faciomaxillary Surgery Clinic, where he was due to extensive skull facial bone injury, after falling from a great height.

The radiological documentation (description of an X-ray) performed immediately after the injury showed: "Photos of part of the facial skull, made by means of multislice computed tomography with three-dimensional image reconstruction, show fragmentation of the mandibular head on the left side with displacement of bone chips to the medial side and to the front" (Fig. 9 A and B).

The direct cause of the patient's request for help was pain coming from the teeth, a significant reduction in dilation of jaws and associated with the above symptoms difficulties in eating. Clinical examination revealed the size of the opening slot - 10 mm and broken tooth crowns: 46, 47 (class III according to Elis) and broken teeth 24 and 31 (class IV-V according to Elis) with significant exposure of the pulp chamber. The pantomography picture confirmed fracture with displacement and fragmentation of the mandibular head on the left and fracture without displacement of the mandibular body, passing through tooth socket 48.

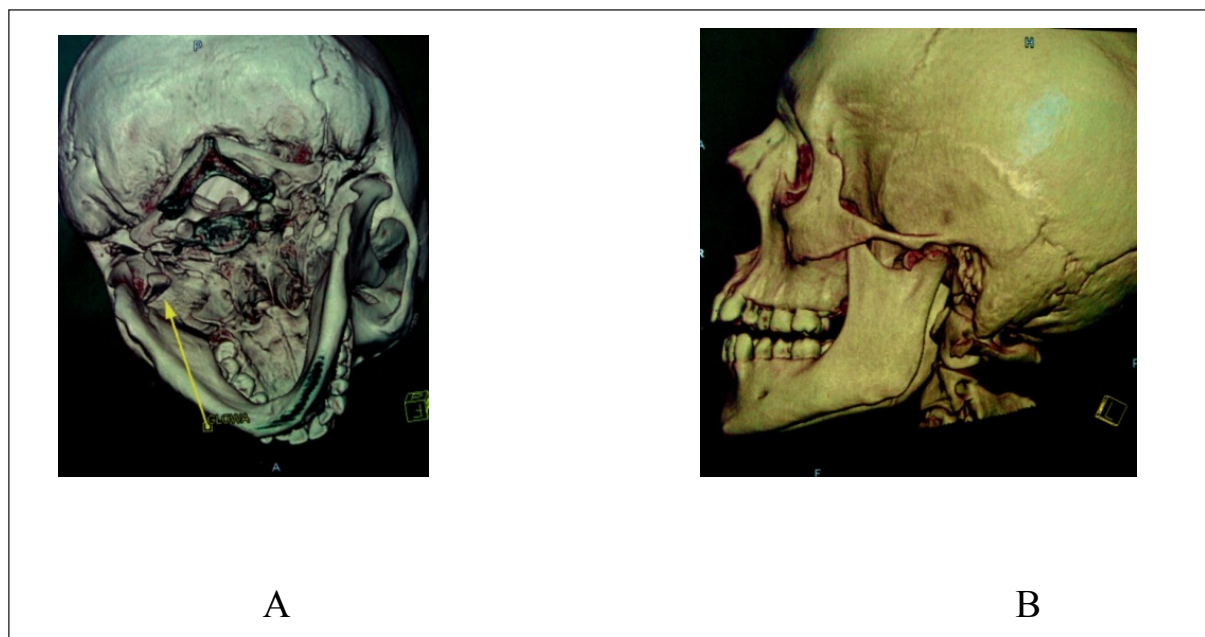

Fig. 9. Photos of the facial skull – the technique of multislice computed tomography

The patient underwent conservative treatment, consisting of applying contemporary wound dressing of damaged teeth and devitalization of teeth with bare dental pulp. Due to the limited aperture of 10 mm, in the first months after the injury, no additional functional studies were performed. Physical rehabilitation was implemented, involving exercises to increase the range of mandibular motion. After several weeks of rehabilitation, further conservative treatment was performed and also a functional examination was carried out with a Zebris JMA device.

The results of the functional examination:

Record of abduction movement shows a strong deviation of the mandible to the left: 10 mm from the midline (Fig. 10).

Significant deprivation of motion in the left (damaged) temporomandibular joint and a small range of motion of the left condylar appendix – 5.3 mm. The device also recorded the retrusive motion, minor-normal on the side of the healthy joint and paradoxically large (nonphysiological) distal range of motion on the diseased side – 4.9 mm (Fig. 11A).

Impairment of right-sided activity – 3.7 and normal motion range to the left. Despite disturbances in the functioning of registered damaged alveolar condyloid the observed range of opening movement was correct and located within the normal scope. The size of opening aperture captured on the receiver was 41.3 mm (Fig. 11B) and was sufficient to effectuate conservative and prosthetic treatment. The patient was also recommended to perform further muscle exercises designed to restore the correct path of abduction and adduction of the mandible.

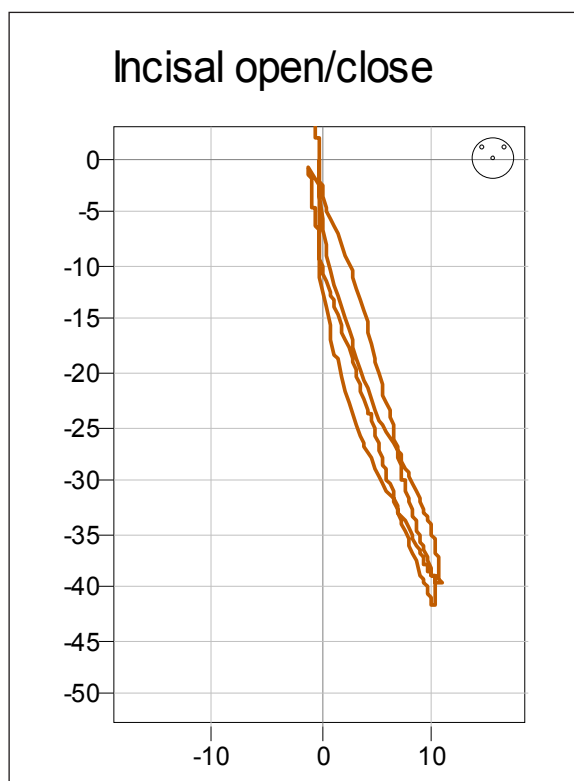


Fig. 10. Graphic record of abduction and adduction movements in the frontal plane, scope of the left-sided deviation in the maximum opening – 10 mm

DISCUSSION OF THE RESULTS

Restoring proper relations between the mandible and the jaw, in the group of patients with temporomandibular joint dysfunctions, is the overriding need [15,27]. The li-

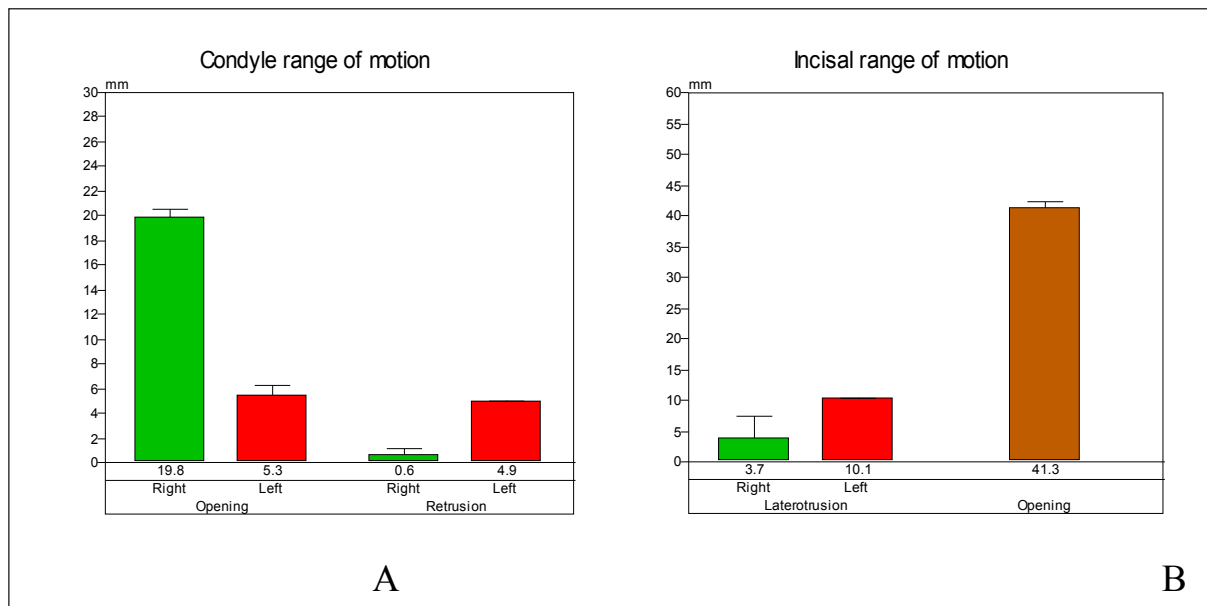


Fig. 11. Graphic recording (Zebris JMA) of movement of mandibular heads and incisal point, after 3 months of muscle training: A – range of motion of both heads of the condylar process in the joints; B – ranges of opening side movements

mitation of mandibular activity is often the consequence of damage to cartilage-bone and/or ligament elements of temporomandibular joints suffering after trauma.

The factors that generate disturbances within the stomatognathic system are among others injuries within the facial part of the skull, including fracture of the condylar process. These represent 12% to 29% of all fractures of the mandible [1, 26]. Mostly they are the result of lesions around the chin. In the treatment of bone fractures of the mandible the main principle is to manipulate bone chips and set them as close as possible to the anatomical position. Therefore the orthopaedic surgical method appears to be the most appropriate. However, anxiety about postoperative complications, reaching 20% of cases [23, 26], encourages managing this type of injury with conservative-orthopaedic intervention. However, the most dreaded menace – permanent mimetic paralysis – occurs, according to some authors (Cieřlik) relatively rarely (0.9%) [5]. The fear of complications involving anatomical difficulties – the location and structure of temporomandibular joints – causes that the prevalent modality is still a non-operative procedure. This involves the repositioning of bone chips by the skin layers, immobilising them with splints [25, 26] and adopting a maxillo-mandibular resort flexible traction for 2-6 weeks. The next phase of treatment is the use of mechanotherapy in order to avoid dysregulation in mobility of the temporomandibular joint. The percentage of patients with a positive, satisfactory result of this treatment is comparable to the outcomes achieved applying the orthopaedic surgical process and is about 50% according to Arkuszewski and Hilt [1].

In discussed case number III only the second stage of this treatment was adopted. Trauma caused by the pa-

tient's bad condition did not allow surgical intervention to be performed. The implementation of bite splint and application of traction were also omitted. The main action was muscle therapy, which aimed to restore the maximum possible efficiency of the masticatory locomotor system.

Additional studies, using computer supported instrumental techniques, have been highly useful in the course of the described matter.

Similar to the feedback of *Panek*, it should be established that an easy to use, lightweight measuring system that is harmless for the patient during the test, such as the Zebris JMA system, can be widely used in clinical diagnosis [19].

In evaluation of the quality of abduction and adduction movements, not only the observation of the incisal point in the clinical trial is helpful, but also the analysis of graphs, showing the simultaneous movement of both condylar processes and their interdependence, as well as observational study of all joint elements' activities in expanse and time. This type of record makes it possible to assess the quality of deviation in a particular movement. It also indicates the joint responsible for the disorder. In this concrete episode, accurate analysis of movement recordings, performed by the damaged mandibular head, allowed exclusion of serious complication occurring in this type of injury, treated mainly surgically – joint ankylosis [1]. Based on the obtained graphs, it can be concluded that, although the anterior movement of left condylar process was blocked, the compensatory mechanisms enabled a quite significant range of abduction motion. The graphic record shows that this was po-

ossible by dint of a slight posterior condyle movement during the described activity.

In the search for reasons for continuing, non-traumatic mobility restriction, we cannot forget inflammatory myopathies and the patient's unwillingness caused by fear of deterioration. In cases of painful and painless myoarthropathy, coexisting cracks in the temporomandibular joints lead to functional limitation of jaw movements [22,27]. In many cases, patients suffer increased levels of depression, although the results of electromyographic tests do not always indicate the coexistence of neurogenic changes in the form of increased tension within the masticatory muscles. According to Dubojska, secondary depression, which might be a sign of lack of acceptance in relation to stressful factors (pain, dysregulation), is an emotional dysfunction, which in certain conditions and among susceptible individuals may cause or exacerbate dysfunctional symptoms [6]. Maintaining this condition – the reduction of muscles' functioning – can lead to muscle shortening and atrophy. The level of masticatory muscles' activity plays a significant role in proper functioning of the masticatory motor system. The graphic records analysis of loose and articulation mandible movements and comparing the electromyographic records before and after the treatment is an important addition to evaluating the treatment effectiveness of temporomandibular movement disorders.

The undeniable advantages of the Zebris JMA device, used for testing, are the educational aspects. It is much easier to motivate the patient to perform intensive exercises if he can watch the treatment progress on a computer screen. The graphic image of condylar processes' kinetics obtained by the appliance, in combination with the results of radiological examination, showing the absence of jaw obstacles that could reduce condylar activity in the joints, demonstrates the muscle or psychological aetiology of disorders. Not always and not every impairment of

masticatory apparatus movement requires complicated splint or pharmacotherapy [13,15,20].

Therapy using muscle training generally is considered as a conservative method of treatment. Stretching, isometric and relaxation exercises are relatively simple and non-invasive, and therefore can be successfully recommended to most of the patients. Muscle exercise routines lead to shortening excessively expanded muscle fibres, while restoring the full length of shortened ones; they also restore the symmetry and the correct tension. The performed evaluation proves that we have to agree with the opinion of Drobka and Karasiński, who in their research, using the above-mentioned therapy, obtained 70% efficacy in the area of mandibular hypermobility treatment [7]. However, it must be remembered that the recommendation of this solution should be preceded by appropriate diagnostic procedures, completed with the correct functional diagnosis. The exercises should be carried out moderately, with graduated intensity, in order to avoid aches, which might discourage patients from undertaking the suggested manner of treatment. Kinesis therapy effectiveness largely depends on the scrupulousness of the patient. In all three discussed cases a satisfactory medicinal effect was achieved. Nonetheless, the patients were informed about the need for constant control of the masticatory functional condition and about the eventuality of further healing.

CONCLUSIONS

1. Muscle training is crucial in restoring the mobility of the mandible, in a range as close as possible to normal, even after extensive trauma of the TMJ.
2. Analysis of the mandibular activity graphic recordings showed that even substantial limitation of one mandibular head's movement, such as head damage, does not significantly affect the range of abduction motion.

REFERENCES

- [1] Arkuszewski P., Hilt T.: The evaluation of treatment results in the group of patients with mandibular head fracture. *Mag. Stomat.*, 2003; 13: 58-61
- [2] Baron S., Karasiński A.: The method of determining the condylar and articular discs position, using MR in the group of patients with masticatory apparatus dysfunction. *Czas. Stomatol.*, 2003; 56: 875-880
- [3] Baron S., Karasiński A., Tarnawska B., Kokot T.: The image of occlusal impetus before and after applying the relaxation splint among patients with diagnosed bruxism. *Prot. Stom.*, 2000; 50: 266-271
- [4] Bereznowski Z., Klajman S.: Computer diagnostics of chewing muscles' dynamic position. *Protet. Stom.*, 2003; 53: 3
- [5] Cieślak T., Skowronek J., Lipiarz L.: Complications in the surgical treatment of condylar fractures. *Czas. Stomatol.*, 2003; 56: 485-489
- [6] Drobek W., Karasiński A.: The research over the effectiveness of mandibular hypermobility conservative treatment. *Prot. Stom.*, 2002; 52: 217-222
- [7] Dubojska A.M.: The psychological background of tension headaches based on literature Review. *Czas. Stomatol.*, 1998; 51: 133-136
- [8] Ferrario V.F., Sforza C., Zanotti G., Tartaglia G.M.: Maximal bite forces in healthy young adults as predicted by surface electromyography. *J. Dent.*, 2004; 32: 451-457
- [9] Gabler M., Reiber T., John M.: Die mehrdimensionale Charakterisierung einer Patientenpopulation mit kranionmandibularen Dysfunktionen. *Dtsch. Zahnärztl. Z.*, 2001; 56: 332-334
- [10] Gerber A.: The logic and mysticism of temporomandibular joints' disorders. *Quintessence*, 2008; 26: 30-42
- [11] Gesch D., Bernhardt O., Alte D., Kocher T., John U., Hensel E.: Malocclusions and clinical signs or subjective symptoms of temporomandibular disorders (TMD) in adults. Results of the population-based Study of Health in Pomerania (SHIP). *J. Orofac. Orthop.*, 2004; 65: 88-103

- [12] Kerstein R.B.: Combining technologies: a computerized occlusal analysis system synchronized with a computerized electromyography system. *Cranio*, 2004; 22: 96-109
- [13] Kostrzewa-Janicka J., Prątnicki M., Anulewicz A., Mierzwińska-Nastalska E.: The effectiveness of treatment using stabilization splints. *Prot. Stom.*, 2007; 57: 397-407
- [14] Magnusson T., Egermark I., Carlsson G.E.: A longitudinal epidemiologic study of signs and symptoms of temporomandibular disorders from 15 to 35 years of age. *J. Orofac. Pain*, 2000; 14: 310-319
- [15] Mieszkowski P., Kleinrok J.: The efficacy evaluation of treatment among patients with masticatory apparatus pain dysfunction, using electrostimulation combined with repositional occlusal splint. *Czas. Stomatol.*, 2003; 56: 56-61
- [16] Nather M., Korzon T.: The study jaw abductor muscles performed for improvement of facial skull fractures treatment. *Czas. Stomatol.*, 1993; 46: 2-3
- [17] Nęcka A.: The change of muscle activity in the stomatognathic system in various clinical situations, taking into account electromyographic studies - literature review. *Dent. Med. Probl.*, 2006; 43: 115-119
- [18] Nilsson I.M., List T., Drangsholt M.: Prevalence of temporomandibular pain and subsequent dental treatment in Swedish adolescents. *J. Orofac. Pain*, 2005; 19: 144-150
- [19] Panek H.: The usage of computer systems in the diagnosis of masticatory functional disturbances. *Protet. Stom.*, 2003; 53: 2
- [20] Pihut M., Wiśniewska G., Majewski S.: The efficiency evaluation of selected chewing muscles' under the impact of occlusal splints, with the aid of electromyographic studies. *Czas. Stomatol.*, 2007; 60: 473-482
- [21] Roark A.L., Glaros A.G., O'Mahony A.M.: Effects of interocclusal appliances on EMG activity during parafunctional tooth contact. *J. Oral Rehabil.*, 2003; 30: 573-577
- [22] Robson F.C.: The clinical evaluation of posture: relationship of the jaw and posture. *Cranio*, 2001; 19: 144
- [23] Siluk J., Kowalczyk R., Zawodny P.: Surgical approach in treatment of 'chirurgical processes' fractures. *Czas. Stomat.*, 2003; 56: 601-608
- [24] Stiesch-Scholz M., Fink M., Tschernitschek H.: Comorbidity of internal derangement of the temporomandibular joint and silent dysfunction of the cervical spine. *J. Oral Rehabil.*, 2003; 30: 386-391
- [25] Suwalska J., Gawor E.: The use of splints in the masticatory motor system dysfunction treatment - based on the literature from recent years (part I). *Prot. Stom.*, 2001; 51: 141-146
- [26] Szwarczyński A., Kucharska M.: Indications for orthopedic and surgical treatment of condylar processes based on the literature and personal experience. *Dent. Forum*, 2004; 31: 61-64
- [27] Tschernitschek H., Schliephake H., Fink M.: Kranionmandibulare Dysfunktion und Halswirbelsäulensymptomatik-wann gibt es Zusammenhänge? *Dtsch. Zahnärztl. Z.*, 2001; 56: 270-272
- [28] Wahlund K.: Temporomandibular disorders in adolescents. Epidemiological and methodological studies and a randomized controlled trial. *Swed. Dent. J. Suppl.*, 2003, 164, 2-64
- [29] Wanyura H., Brudnicki A., Stopa Z.: The results of condylar fractures treatment using miniplate osteosynthesis retromandibular approach. *Czas. Stomatol.*, 2003; 56: 674-682
- [30] Watanabe K.: The relationship between dentofacial morphology and the isometric jaw-opening and closing muscle function as evaluated by electromyography. *J. Oral Rehabil.*, 2000; 27: 639-645
- [31] Winocur E., Littner D., Adams I., Gavish A.: Oral habits and their association with signs and symptoms of temporomandibular disorders in adolescents: a gender comparison. *Oral Surg. Oral Med. Oral Pathol. Oral Radiol. Endod.*, 2006; 102: 482-487

The authors have no potential conflicts of interest to declare.