

Received: 2012.02.02
Accepted: 2012.04.03
Published: 2012.04.19

Crossed renal ectopia: can it be a diagnostic problem?

Ektopia skrzyżowna nerki: czy jest to problem diagnostyczny?

Dorota Polak-Jonkisz¹, Konstancja Fornalczyk¹, Kinga Musiał¹,
Urszula Zaleska-Dorobisz², Wojciech Apoznański³, Danuta Zwolińska¹

¹ Department of Pediatric Nephrology, Medical University of Wrocław, Poland

² Department of General and Pediatric Radiology, Medical University of Wrocław, Poland

³ Department of Pediatric Surgery and Urology, Medical University of Wrocław, Poland

Summary

Crossed renal ectopia (C-RE) is a rare congenital anomaly in which both kidneys are located unilaterally. The crossed kidney is situated on the side opposite to its ureteral orifice and usually lies below the normal kidney. The frequency of this malformation is estimated at 0.05% to 0.1%. Most of the patients remain asymptomatic. In other cases C-RE is diagnosed incidentally on routine ultrasonography, due to the presence of unspecific symptoms. The diagnosis of C-RE is possible due to a wide range of imaging techniques: US, IVU, CT, MRI, and TcDMSA scan. Among them IVU, CT, and MRI have the highest degree of confidence. The aim of this retrospective study was to present our own experience with 5 children affected with C-RE, emphasizing the differences in clinical picture and low sensitivity of ultrasound images. In all of them the final diagnosis was established by IVU or MRI.

Key words: crossed renal ectopia • congenital anomaly • imaging studies • children

Streszczenie

Skrzyżowana ektopia nerki (C-RE) jest rzadką wadą rozwojową polegającą na przemieszczeniu nerki na stronę przeciwną, przy czym moczowód nerki ektopicznej przecina linię pośrodkową ciała i uchodzi do pęcherza moczowego w miejscu typowym. Etiopatogeneza anomalii pozostaje nieustalona. Częstość występowania przemieszczenia skrzyżowanego nerki szacuje się na 0,05–0,1%. Wielu pacjentów z C-RE pozostaje niezdiagnozowanych z powodu braku objawów. U pozostałych wada ta rozpoznawana jest badaniem USG przypadkowo w trakcie diagnostyki nawracających bólów brzucha, zakażeń układu moczowego, krwinkomoczu lub krwiomoczu. C-RE może także współistnieć z wadami innych układów: kostno-stawowego, pokarmowego i moczowo-płciowego. Te ostatnie występują najczęściej, a wśród nich dominują wodonercze i odpływ pęcherzowo-moczowodowy. W rozpoznaniu C-RE pomocne są różnorodne badania obrazowe, takie jak USG, urografia, TK i MNR, a także DMSA. Celem tego retrospektywnego badania było przedstawienie własnych doświadczeń dotyczących trudności diagnostycznych C-RE u 5 dzieci. W pracy podkreślono różnice w przebiegu klinicznym i niewielką czułość obrazów USG. We wszystkich przypadkach ostateczna diagnoza została potwierdzona przez IVU lub MR.

Słowa kluczowe: skrzyżowana ektopia nerki • wady rozwojowe • diagnoza obrazowa

Full-text PDF: <http://www.phmd.pl/fulltxt.php?ICID=991491>

Word count: 1639
Tables: 1
Figures: 2
References: 13

Author's address: Dorota Polak-Jonkisz dr n med., Department of Pediatric Nephrology, Medical University of Wrocław, ul. Borowska 213, 50-556 Wrocław, Poland; e-mail: dpjonkisz@nefped.am.wroc.pl

Abbreviations: **angio-CT** – angio-computed tomography; **C-RE** – crossed renal ectopia; **CT** – computed tomography; **CystoUS** – color-Doppler cystosonography with echo contrast (cysto-ultrasonography); **GFR** – glomerular filtration rate; **GIT** – gastrointestinal tract; **IVU** – intravenous urogram; **MRI** – magnetic resonance imaging; **S-RE** – simple renal ectopia; **TcDMSA scan** – Tc99m dimercaptosuccinic acid scintigraphy; **US** – ultrasonography; **UT** – urinary tract; **UTI** – urinary tract infection; **VCUG** – voiding cystourethrography; **VUR** – vesicoureteral reflux.

INTRODUCTION

Crossed renal ectopia (C-RE) is a rare developmental anomaly in which both kidneys are located on the same side of the body. The ectopic kidney is usually located below the normal kidney and its ureter crosses the spine and has a normal opening in the bladder.

The incidence of this defect in the general population is estimated at 0.05 to 0.1%, with a slight male predominance [1,8,11]. Approximately 90% of ectopic kidneys are fused by their lower pole with the normal kidney and they are usually smaller [1]. The left kidney is displaced more often than the right one [1,3,8].

The etiopathogenesis remains uncertain. Many hypotheses have been put forward, regarding disorders that play a role in the formation of this developmental abnormality. According to Wilmer's concept, crossed renal ectopia is a result of pressure exerted, on a renal unit moving rostrally, by abnormally positioned umbilical arteries. The kidney eventually reaches a location of least resistance, i.e. opposite to its normal position. Other studies emphasize the relation between renal anomaly and abnormal ureteral bud migration which, when moving to the opposite side, induces differentiation of the other kidney. Teratogenic factors and genomic mutations occurring familiarly or arising *de novo* have a significant impact on the final location of the kidneys.

At the end of the 1950s Mc Donald and McCellan modified the division of ectopic crossed kidney as follows: renal ectopia with fusion; renal ectopia without fusion; solitary renal ectopia; bilateral renal ectopia [7,11].

Many patients with C-RE remain undiagnosed due to lack of symptoms.

In the rest, this defect is diagnosed incidentally during routine pre- and postnatal ultrasound examinations and also during investigations of other diseases (e.g. urinary tract infection (UTI), urolithiasis and Wilms' tumor), often associated with C-RE. The anomaly may be accompanied by other abnormalities, both in the urinary tract (dysplastic kidney, abnormal rotation, hydronephrosis, vesicoureteral reflux (VUR), renal tumors), skeletal, digestive and cardiovascular systems [1,7,11].

A wide range of imaging tests are helpful in diagnosing C-RE, such as ultrasound (US), intravenous urogram (IVU), computed tomography (CT), magnetic resonance imaging (MRI), as well as Tc99m dimercaptosuccinic acid scintigraphy (TcDMSA).

The aim of this study was to present our own experience concerning 5 children with C-RE, emphasizing the differences in clinical picture and low sensitivity of ultrasound images.

PATIENTS AND METHODS

The study group consisted of 5 children (3 girls, 2 boys) aged from 3 months to 12 years. Three children were referred to hospital with suspected renal agenesis on the basis of ultrasound examination, which was performed in view of recurrent abdominal pain in 2 cases and in a 3-month-old infant due to symptoms of regurgitation and irritability during urination. All of these children had a history of recurrent UTIs. A 9-year-old boy born with a myelomeningocele and a neurogenic bladder was admitted for urodynamic studies, as part of routine qualification for surgery (bladder augmentation). Only in one girl, with recurrent abdominal pain, was a suspicion of an ectopic kidney raised. No anomalies were found in 4 children who underwent prenatal ultrasound examination and in one child prenatal ultrasound was not performed.

In all the patients, blood tests (especially for determining renal function) and blood pressure measurements were performed.

Demographic and medical data on patients prior to hospitalization are given in Table 1.

A final diagnosis of C-RE with fusion in all children was based on IVU studies. In four of them, the left kidney was displaced to the right (Figure 1) and in one case the right kidney to the left. Furthermore, only in one patient was the anomaly suggested by a DMSA scan. Based on Doppler ultrasound a suspicion of vascular anomaly in a 12-year-old girl was raised; therefore an MRI was performed, confirming an abnormal passage of the left renal artery (Figure 2). In another child with a positive family history of nephrolithiasis, additionally hyperoxaluria and hyperuricosuria

Table 1. Demographic and medical data on patients prior to hospitalization

Age/Sex	Family history	Data from prenatal period and after birth assessment	Medical history prior to admission to the Department of Pediatric Nephrology			
			Clinical symptoms	Additional tests findings	Coexisting conditions	Cause of hospitalization
1. 3-m-th old/F	Non-significant	Prenatal US- normal Delivery at 34 weeks Apgar score 7	Regurgitation, irritability during urination	Significant bacteriuria US-left kidney agenesis	Gastro-esophageal reflux	Recurrent urinary tract infection, urinary tract anomaly
2. 2.5-year-old/F	Non-significant	Prenatal US- normal Delivery at 38 weeks Apgar score 8	abdominal pain	Leucocyturia, microscopic Hematuria Significant bacteriuria Anaemia US-right kidney agenesis		Recurrent urinary tract infection, urinary tract anomaly
3. 5-year-old/M	Urolithiasis	Prenatal US- normal Delivery at 39 weeks Apgar score 9	Recurrent abdominal pain	Microscopic hematuria US- left kidney agenesis with double collecting system of the right kidney		Microscopic hematuria and urinary tract anomaly
4. 9-year-old/M	Drug and alcohol abuse in mother; no gynecological follow up during pregnancy	No prenatal work up; delivery at 37 weeks Apgar score 7, multiple congenital abnormalities: myelomeningocele, anal atresia	Dysuria, Constipation	Significant bacteriuria US- left kidney agenesis „small” bladder	Neurogenic bladder, anal atresia	Recurrent urinary tract infection, urinary tract anomaly, neurogenic bladder
5. 12-year-old/F	Non-significant	Prenatal US- normal Delivery at 38 weeks Apgar score 9	Recurrent abdominal pain	Non-significant past history US+ Doppler: renal ectopia	Irritable bowel syndrome	Recurrent urinary tract infection, urinary tract anomaly

were found. In one case analyzed in our study, an additional developmental anomaly, anal atresia, was detected. It coexisted in a boy with a neurogenic bladder due to a myelomeningocele, corrected immediately after birth. The majority of children had a history of UTIs. VUR was excluded in all patients. Renal function was normal and blood pressure values were within the normal range.

Selected images of C-RE visualized by IVU and MRI are presented below.

DISCUSSION

Crossed renal ectopia (C-RE) is an uncommon congenital anomaly which was first described by Pamarolus in 1654. The reported incidence of C-RE is 1:7500 autopsies, whereas it is extremely rare in clinical practice (1 in 14 000 pediatric admissions) [1]. The anomaly usually remains asymptomatic; therefore it is mainly detected incidentally. According to Van den Bosch et al. prenatal ultrasonography may suggest the diagnosis of renal ectopia [12]. In this study, none of our children was diagnosed with C-RE prenatally.

Among the 4 variants of C-RE, type 1, with left kidney crossed to the right, is the most frequent one. The ectopic kidney is mainly located below the normal one (inferior ectopic kidney) and it is usually malrotated. All presented cases were inferior ectopic kidneys. In 2 individuals incomplete rotation of the ectopic kidney was demonstrated. In general, the

occurrence of C-RE with fusion is higher than C-RE without fusion (3:1) [1,2,7,8]. In our study, C-RE with fusion was found in all cases, which is concordant with overall statistics.

C-RE is mostly diagnosed on routine renal US, performed in patients presenting with non-specific general or genitourinary symptoms.

In neonates the most frequent symptoms are failure to thrive, feeding difficulties, e.g. regurgitation, and irritability during urination [1]. Similar symptoms were observed in our 3-month-old female patient. In pre-school children and adolescents, non-specific recurrent abdominal pain, change of bowel movement habits, dysuria and hematuria are most often reported. Our own and reference data indicated that abdominal pain is the leading symptom in pediatric patients with a final diagnosis of C-RE. It is characterized by atypical localization and variable intensity. In the majority of our patients abdominal pain could have been associated with urinary tract infection too.

C-RE can present as an isolated anomaly or may occur in association with urogenital and anorectal malformations, intestinal malrotation, urolithiasis and Wilms’ tumor [1,4,5,7]. Among the urinary tract abnormalities coexisting with C-RE, VUR and hydronephrosis were most frequently reported [1,5,6]. In our three patients suspected of VUR, voiding cystourethrography showed no abnormalities. Furthermore, a mild renal pelvis dilation was revealed in two children. In

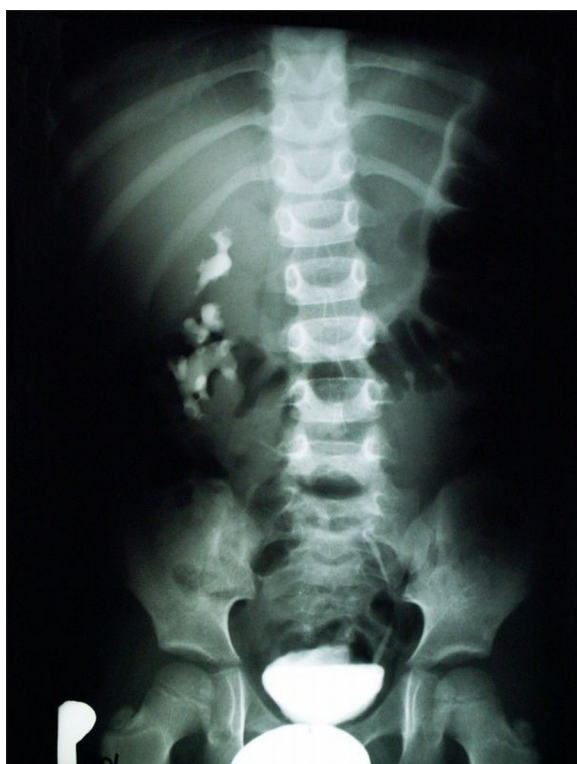

Fig. 1. Image of IVU shows both kidneys located unilaterally on the right side; ectopic left kidney, malrotated and located below the right one. Ureteral orifices are in their normal anatomic positions

a 12-year-old girl, secondary dilation of the renal pelvis of the normal kidney was caused by the crossing vessels of the ectopic one (Figure 2). Calisti et al. postulated that vascular anomalies found in C-RE may lead to dysfunction of the ectopic kidney [4], whereas Van den Bosch et al. found no significant differences in GFR, blood pressure and proteinuria between S-RE (simple renal ectopia) and C-RE individuals in childhood [12]. Additionally, there were no renal function abnormalities present in our patients.

In 2 of our patients functional gastrointestinal tract (GIT) disorders were found: gastroesophageal reflux and irritable bowel syndrome. In one case (boy) with a neurogenic bladder due to myelomeningocele, coexisting imperforate anus was detected. Due to frequent association of crossed renal ectopia with GIT abnormalities, a diagnosis of C-RE may be considered as an indication for GIT diagnostic tests [1].

There are single studies reporting on Wilms' tumor in C-RE, but the higher incidence of oncological diseases in patients affected with C-RE was not confirmed [11]. In one of our patients, a 5-year-old boy with C-RE, microscopic haematuria with hyperoxaluria and hyperuricosuria was detected. There was a family history of urolithiasis; however, this condition may accompany C-RE as well [1,4].

The diagnosis of C-RE is possible due to a wide range of imaging techniques including ultrasonography, intravenous urography, computed tomography, magnetic resonance imaging and Tc99m dimercaptosuccinic acid scintigraphy.

US is the first imaging test that starts the diagnostic trial; however, its degree of confidence in detecting C-RE is rather

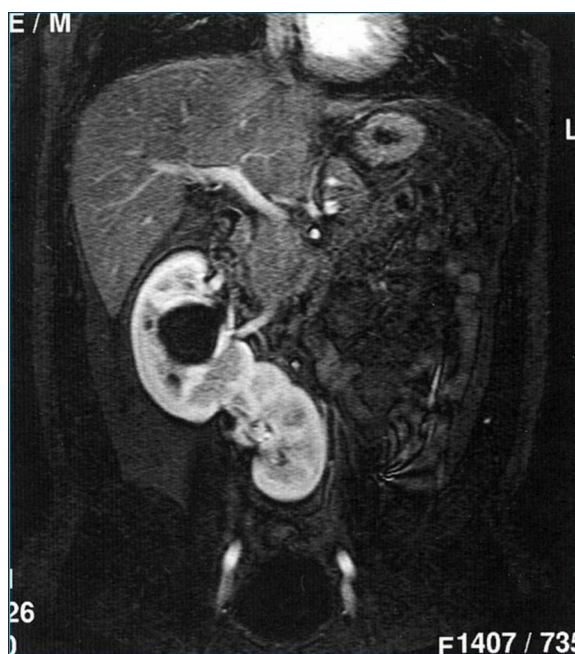


Fig. 2. MRI seq. T1/T2 shows crossed renal ectopia. Right kidney located in the normal position with slight malrotation and pelvic dilation. Left kidney on the right side fused with the right kidney with the upper pole of the right kidney. Ureteral orifices are in normal anatomic locations

low. US usually reveals the absence of one of the kidneys in its normal location, dilation of the renal pelvis and increased size of the solitary visualized kidney. Such a finding may suggest unilateral renal agenesis and requires additional laboratory tests and imaging techniques to confirm the final diagnosis. In fact, in our study in 4 of 5 children US images suggested renal agenesis. In addition, in one of the patients the only kidney to be revealed was described to have a duplex pericaliceal system (patient no. 3 in table 1). Subsequently, in such a case a TcDMSA scan, visualizing a solitary and enlarged kidney of abnormal shape, can be a possible diagnostic aid. Furthermore, an imaging study that helps to clarify the diagnosis is IVU, which was performed in most of our patients. In one of them, with coexisting vessel anomaly suspicion, an abdominal MRI confirmed the final diagnosis of C-RE and revealed changes in the left renal artery. Contrast enhanced CT, MRI and angio-CT are among the imaging tests of highest sensitivity. Due to higher economic costs of the above-mentioned tests they are used sparingly prior to surgical treatment, for accurate visualization of the anatomy of organs and passage of vessels [1,10,13].

According to Bauer, in every patient with C-RE, even despite the absence of recurrent urinary tract infections and associated anomalies, VCUG should be performed [12]. Arena et al. claim that, apart from TcDMSA scan, VCUG in males and color-Doppler cystosonography with echo contrast (CystoUS) in female patients with C-RE is necessary [1]. Voiding cystourethrography performed in our patients showed no presence of VUR.

CONCLUSION

Nonspecific symptoms of C-RE may make the way to final diagnosis uneasy. The condition was revealed incidentally and

the initial US finding had to be verified by further sophisticated imaging techniques. Although C-RE usually does not require

surgical treatment, children with this anomaly should be carefully followed up due to potential associated abnormalities.

REFERENCES

- [1] Arena F., Arena S., Paolata A., Campenni A., Zuccarello B., Romeo G.: Is a complete urological evaluation necessary in all newborns with asymptomatic renal ectopia? *Int. J. Urol.*, 2007; 14: 491–495
- [2] Arrieta M.U., Trapote R.A., Lizarraga D.A.: Renal position and fusion anomalies. *Ann. Pediatr. (Barc.)*, 2011; 75: 329–333
- [3] Boyan N., Kubat H., Uzum A.: Crossed renal ectopia with fusion: report of two patients. *Clin. Anat.*, 2007; 20: 699–702
- [4] Calisti A.M., Perrotta L., Oriolo D., Ingianna D., Miele V.: The risk of associated urological abnormalities in children with pre and postnatal occasional diagnosis of solitary, small or ectopic kidney: is a complete urological screening always necessary? *World J. Urol.*, 2008; 26: 281–284
- [5] Guarino N., Tadini B., Camardi P., Silvestro L., Lace R., Bianchi M.: The incidence of associated urological abnormalities in children with renal ectopia. *J. Urol.*, 2004; 172: 1757–1759
- [6] Hunziker M., Kutasy B., D'Asta F., Puri P.: Urinary tract anomalies associated with high grade primary vesicoureteral reflux. *Pediatr. Surg. Int.*, 2012; 28: 201–204
- [7] Lin V.C., Weng H.C., Kian-Lim E., Lin I.C., Yu T.J.: An atrophic crossed fused kidney with an ectopic vaginal ureter causing urine incontinence. *Urology*, 2010; 76: 55–56
- [8] McDonald J.H., McClellan D.S.: Crossed renal ectopia. *Am. J. Surg.*, 1957; 93: 995–1002
- [9] Nursal G.N., Büyükdereli G.: Unfused renal ectopia: a rare form of congenital renal anomaly. *Ann. Nucl. Med.*, 2005; 19: 507–510
- [10] Romero F.R., Chan D.Y., Muntener M., Bagga H.S., Brito F.A., Kavoussi L.R.: Laparoscopic heminephrectomy for renal cell carcinoma in cross-fused ectopic kidney. *Urology*, 2007; 69: e11–e13
- [11] Stimac G., Dimanovski J., Ruzic B., Spajic B., Kraus O.: Tumors in kidney fusion anomalies-report of five cases and review of the literature. *Scand. J. Urol. Nephrol.*, 2004; 38: 485–489
- [12] van den Bosch C.M., van Wijk J.A., Beckers G.M., van der Horst H.J., Schreuder M.F., Bökenkamp A.: Urological and nephrological findings of renal ectopia. *J. Urol.*, 2010; 183: 1574–1578
- [13] Yano H., Konagai N., Maeda M., Itoh M., Kuwabara A., Kudou T., Ishimaru S.: Abdominal aortic aneurysm associated with crossed renal ectopia without fusion: case report and literature review. *J. Vasc. Surg.*, 2003; 37: 1098–1102

The authors have no potential conflicts of interest to declare.